

STUDY OF PLACENTAL MORPHOLOGY IN PREGNANCY-INDUCED HYPERTENSION AND ITS CORRELATION WITH FOETAL OUTCOME

Keerti Sahi¹, Umarani M. K²

¹Postgraduate, Department of Pathology, MMC and RI, Mysuru, Karnataka, India

²Professor, Department of Pathology, MMC and RI, Mysuru, Karnataka, India

Received : 05/12/2023
Received in revised form : 01/02/2024
Accepted : 16/02/2024

Keywords:

Placenta; Preeclampsia;
Morphometry; Morphology.

Corresponding Author:

Dr. Keerti Sahi

Email: keertisahireddy@gmail.com

DOI: 10.47009/jamp.2024.6.1.419

Source of Support: Nil,

Conflict of Interest: None declared

Int J Acad Med Pharm
2024; 6 (1); 2107-2112



Abstract

Background: Placenta is the functional unit between mother and fetus and therefore any pathology in placenta will also affect the foetus. A thorough examination of the placenta provides much insight about the prenatal life and therefore can be informative for later management of mother and newborn. The objectives are to study the spectrum of placental changes in pregnancy-induced hypertension (PIH) in comparison with placenta of normal pregnancy and correlating with foetal outcome between two groups. **Materials and Methods:** The present study was a case-control study with sample size of 80 (40 normal; 40 preeclamptic). A comparative study was carried out which included detailed external examination of the placenta and microscopic study of hematoxylin-eosin stained slides. A brief history of birth weight and quick examination for congenital defects was done to correlate the placental changes in PIH with fetal outcome. Results were compared and correlated between two groups using statistical analysis. **Result:** The placental weight and volume were significantly decreased in the preeclamptic group. Incidence of gross features like retroplacental hematoma and infarction and the microscopic features like syncytial knot formation, cytotrophoblastic cellular proliferation and villous stromal fibrosis were significantly more in the study group than the control group. Study group was also associated with poor fetal outcome. **Conclusion:** Preeclampsia adversely affects the morphometry and morphology of the placenta which in turn have an impact on fetal outcome. Present study emphasizes the importance of in-utero measurement of placental parameter like placental volume which further helps in better management of at risk fetus.

INTRODUCTION

Word 'placenta' is derived from the Latin word which means 'flat cake'.^[1] It acts as a functional unit between the mother and fetus by providing oxygen and nourishment to the fetus. Study of placenta in medical and surgical illness complicating pregnancy provides information helpful for the obstetrician and neonatologist to know about perinatal morbidity and mortality and subsequent pregnancy outcome. Hence a careful examination of the placenta with formalin fixed tissue allows to understand the nature and duration of the process which had occurred during the gestational period.

Abnormalities in the development of placenta during early stages of pregnancy leads to placental underperfusion. Subsequently, there is a release of antiangiogenic factors in to the maternal circulation with alteration of maternal systemic endothelial function. This causes hypertension and subsequent placental changes.^[2] Five to ten percent of all pregnancies are complicated by hypertensive

disorders and together they form the deadly triad along with haemorrhage and infection which contributes greatly to maternal morbidity and mortality. Among these disorders, preeclampsia syndrome, either alone or combined with chronic hypertension, is the most dangerous.^[3] Unless delivery supervenes, these changes ultimately result in multiorgan involvement which gives rise to a wide range of clinical spectrum, from an attenuated manifestation to one of terrible deterioration that is life threatening for both mother and fetus. They majorly contribute to prematurity of the fetus and haemorrhage and cardiovascular diseases in mother. In addition, they are associated with foetal growth restriction and prematurity leading to perinatal morbidity and mortality.

Hence, there is a need for a detailed examination of placenta which helps in revealing the various abnormalities that contribute to the disorder of pregnancy. This study is an attempt to observe and to compare the morphometric, gross and microscopic features in preeclamptic and normal placenta.

Objectives

- To study the spectrum of placental changes in pregnancy-induced hypertension (PIH) in comparison with placenta of normal pregnancy.
- To correlate placental changes in PIH with fetal outcome.

MATERIALS AND METHODS

The present study was a prospective, case- control study conducted in the department of Pathology, Mysore Medical College and Research Institute, Mysore during December 2018 to May 2020.

Inclusion Criteria

- Pregnancy above 20 weeks of gestation
- Blood pressure > 140/90 mmHg

Exclusion Criteria

- History of maternal diseases such as chronic renal disease, essential hypertension.
- Pre-existing diabetes mellitus and gestational diabetes

80 placentas were studied out of which 40 placentas were from the pregnant females with uncomplicated/normal pregnancy which were taken as control group and 40 placentas from the pregnant females with pregnancy induced hypertension.

Detailed history of the mother such as name, age, parity, address, previous obstetric history, past history of major illness, present medical history were recorded on predesigned proforma. Birth weight and any admissions of new-borns to NICU were obtained from the record.

Placenta with attached membranes were collected immediately after delivery and washed in running tap water to clear off the blood and sent for histopathological examination. Gross parameters like weight, diameter, thickness, area, volume and circumference of the placenta were noted and subjected for further tissue processing. Once the microscopic examination was done, findings were compared between two groups. The placental changes were correlated with duration and severity of preeclampsia and as well as with the fetal outcome. Approval for the study was taken from the Ethical committee.

Statistics: Analysis was done using SPSS software. Version 16.0. Descriptive statistics employed in the present study are mean, standard deviation, frequency and percent. Comparison of various parameters between two groups was analysed by student's "t" test and categorical data was analysed by Chi-square test. The correlation procedure was done using Pearson's correlation coefficient with its significance level. Level of significance was set at 0.05.

RESULTS

In the present study, more number preterm delivery cases belonged to the hypertensive group [Table 1]. The mean birth weight of new born in preeclamptic

group is less than that of newborns of the control group with the mean value of 2520 ± 724.16 and 2844 ± 345.12 respectively. P value is 0.013 which is statistically significant [Table 2]. The mean placental weight in preeclamptic group is reduced than the control group and is statistically significant with a P value of 0.000. The mean placental volume is again decreased in the preeclamptic group when compared to the control group. This is also statistically significant with a P value of 0.009 [Table 3].

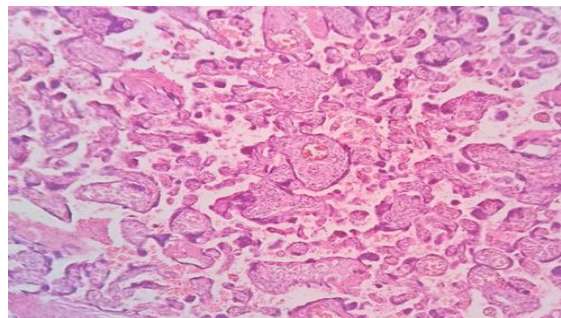


Figure 1: Syncytial Knots

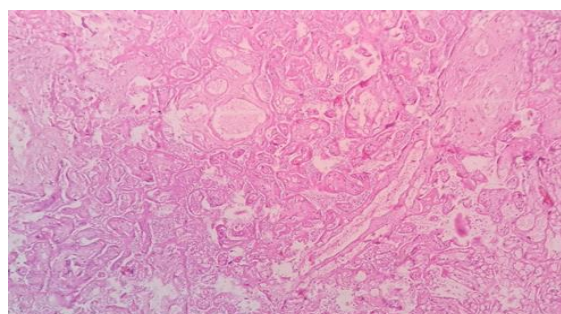


Figure 2: Infarction

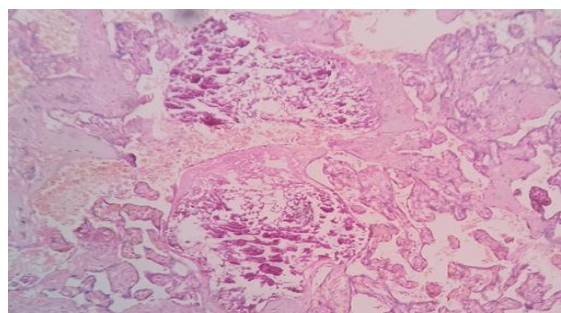


Figure 3: Calcification

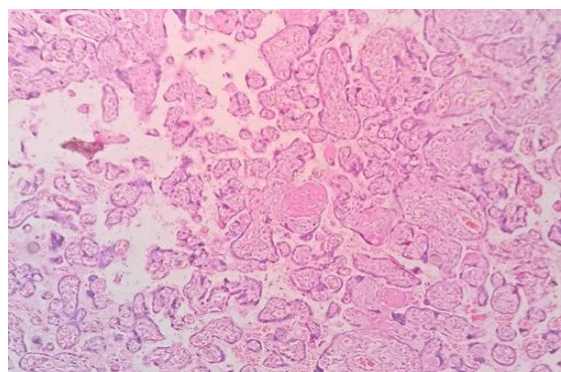


Figure 4: Fibrinoid degeneration

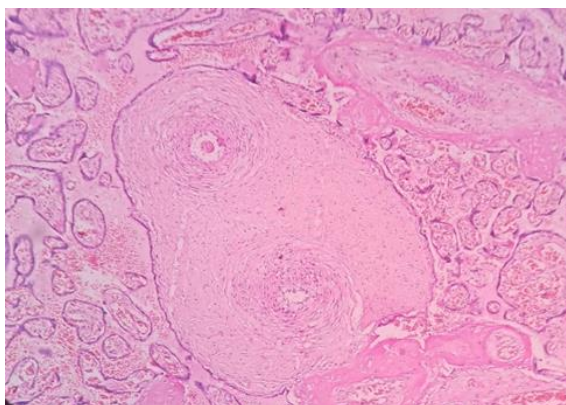


Figure 5: Villous fibrosis

The incidence of retroplacental hematoma is significantly increased in the study group when compared to the control group with a P value of 0.087. But, there is no significant difference in the occurrence of infarction and calcification between two groups with P values of 0.259 and 0.629 respectively [Table 5]. There is significant increase

in the mean number of areas/LPF of syncytial knot formation, cytotrophoblastic cellular proliferation and villous stromal fibrosis. These differences are statistically significant [Table 6].

In the present study, there is a negative correlation between severity of preeclampsia and the placental morphometric features like placental weight and volume which means, with increasing severity of preeclampsia, there is a significant decrease in the placental weight and volume [Table 7]. In this study, we did not find a significant correlation between the severity of preeclampsia and histomorphologic features, i.e., with increasing severity of preeclampsia, there is no statistically significant increase in the mean number of areas of syncytial knot formation/LPF, cytotrophoblastic cellular proliferation/LPF and villous stromal fibrosis/LPF [Table 8]. In this study, there is a highly significant positive correlation between placental morphometry and fetal outcome, i.e. with the decrease in placental morphometric values, fetal outcome will be adversely affected [Table 9].

Table 1: Distribution of cases according to gestational age

Gestational age groups (weeks)	Cases	Controls
28 - 32	10	-
33- 36	2	-
37 - 40	28	40

In the present study, more number preterm delivery cases belonged to the hypertensive group

Table 2: comparison of the fetal birth weight

	Cases Mean± SD	Controls Mean± SD	P value
Fetal birth weight (gms)	2520±724.16	2844±345.12	0.013

The mean birth weight of newborn in preeclamptic group is less than that of newborns of the control group with the mean value of 2520±724.16 and 2844±345.12 respectively. P value: 0.013(statistically significant).

Table 3: Comparison of the NICU admissions of newborns

	Cases		Controls	
	Yes	No	Yes	No
Number of Newborns admitted in NICU	6	34	1	39

In this study, NICU admissions were more in newborns of preeclamptic mothers.

Table 4: Comparison of placental morphometry

Placental morphometry	Cases Mean± SD	Controls Mean± SD	P value
Placental weight (gms)	486.32±131	603.30±100	0.000
Placental volume (cc)	374012±192	506.55±245	0.009

The mean placental weight in preeclamptic group is reduced than the control group and is statistically significant with a P value of 0.000. The mean placental volume is again decreased in the preeclamptic group when compared to the control group. This is also statistically significant with a P value of 0.009.

Table 5: Comparison of placental gross morphology

Placental gross morphology		Cases	Controls	P value
Retroplacental hematoma	Present	8	2	0.04
	Absent	32	38	
Infarction	Present	7	4	0.259
	Absent	33	36	
Calcification	Present	2	2	0.692
	Absent	38	38	

The incidence of retroplacental hematoma is significantly increased in the study group when compared to the control group with a P value of 0.087. But, there is no significant difference in the occurrence of infarction and calcification between two groups with P values of 0.259 and 0.629 respectively.

Table 6: Comparison of placental histomorphology

Placental histomorphology	Cases Mean± SD	Controls Mean± SD	P value
Mean number of areas of syncytial knot formation / LPF	20.90±4.13	9.52±3.62	<0.001
Mean number of areas of cytotrophoblastic cellular proliferation / LPF	12.77±3.23	4.27±2.24	<0.001
Mean number of areas of villous stromal fibrosis	4.60±2.10	1.60±1.15	<0.001

There is significant increase in the mean number of areas/LPF of syncytial knot formation, cytotrophoblastic cellular proliferation and villous stromal fibrosis. These differences are statistically significant.

Table 7: Correlation of placental morphometry with severity of preeclampsia in study group

	Placental weight	Placental volume
Diastolic blood pressure	-0.423	-0.293

In the present study, there is a negative correlation between severity of preeclampsia and the placental morphometric features like placental weight and volume which means, with increasing severity of preeclampsia, there is a significant decrease in the placental weight and volume.

Table 8: Correlation of placental histomorphology with severity of preeclampsia in study group

	Syncytial knots/LPF	Cytotrophoblastic proliferation / LPF	Villous stromal fibrosis
Diastolic BP	-0.030	-0.242	-0.045

In this study, we did not find a significant correlation between the severity of preeclampsia and histomorphologic features, i.e., with increasing severity of preeclampsia, there is no statistically significant increase in the mean number of areas of syncytial knot formation/LPF, cytotrophoblastic cellular proliferation/LPF and villous stromal fibrosis/LPF.

Table 9: Correlation of placental morphometry of fetal outcome

	Fetal birth weight	P value
Placental weight	+0.813	0.000
Placental volume	0.767	0.000

In this study, there is a highly significant positive correlation between placental morphometry and fetal outcome, i.e. with the decrease in placental morphometric values, fetal outcome will be adversely affected.

DISCUSSION

Fetal and placental growth restrictions are usual manifestations of preeclampsia. Fetal growth is a useful marker for fetal well-being and gives an insight about the degree and nature of hazards that the fetus had been subjected during antenatal period. Studies have declared that preeclampsia is a significant risk factor in the development of IUGR in the nonanomalous infant.^[4,5]

This study shows fetal weight is significantly reduced in the hypertensive group than in the control group. These findings correlated with studies of Pradeep S Londhe (2011).^[6]

Placenta normally weighs 400 to 800 gms at term. In this study, significant reduction of placental weight was noticed in the preeclamptic group. Studies conducted by Fox have shown that placenta tend to be smaller in preeclampsia than those in uncomplicated pregnancies.^[7] Kher and Zawar have reported reduced placental weight in cases of higher grades of hypertension, while placenta from cases of mild PE were reported to weigh within normal range.^[8]

In the present study, the decrease in placental weight has a significant negative correlation with increasing severity of PE, similar to the results obtained by Majumdar et al in his study.^[9] In our study, mean

placental volume is significantly decreased in preeclamptic placentae similar to the observations noted by Pradeep et al and Majumder et al in their study.^[9,10]

Our study showed a significant increase in retroplacental hemorrhages (RPH) in preeclamptic pregnancies when compared to the control group. Studies done by Navbir P et al, Fox et al. have noted that a high proportion of placentae with RPH belonged to the preeclamptic group.^[11,12] Study done by Kurdukar et al showed no significant difference between normal and PIH groups with a percentage 12% and 12.2% respectively.^[13]

Since most retro placental hemorrhage(RPH) are the result of maternal vascular disease or trauma, assessment of the decidual spiral arterioles is necessary. Therefore one must examine the adjacent portions of decidua especially in the decidua capsularis for atherosclerosis and thrombosis of these vessels. Sometimes, the etiology remains obscure when vascular changes are not noticed.

Infarcts are the necrotic villous tissue due to insufficient blood supply. Infarcts are firm, condensed dead areas of villous tissue that often involves the entire thickness of the placenta.

In this study, there was an increase in the incidence of infarction in the preeclamptic group and the incidence increases with increasing severity of the

disease. Studies done by Singhal L et al, Kambale T et al and Kurdukar et al have shown that there is statistically significant association of PIH group to placental infarcts.^[1,13,14]

The P value for calcification is 0.6 in this study which is statistically insignificant. Similar findings were given by Brandt (1973).^[15] Whereas studies done by Singhal L et al, Kambale T et al revealed the significant increase in the calcification in PIH groups.^[1,14]

Microscopic examination of placenta from preeclamptic pregnancies showed a significant increase in syncytial knot formation, villous cytotrophoblastic proliferation, villous fibrinoid degeneration and villous stromal fibrosis when compared to the control group.

Study done by CR Gore et al, have found that mean number of syncytial knots was increased in PIH group when compared to the control group. 16 Kurdukar et al found an increase in the knot count with 84% cases of severe PIH and 100% cases of eclampsia.^[17] Similar results have been observed by D Salmani et al.^[18] A E P Heazell et al have concluded from their study, that the increased number of syncytial knots in placenta from pregnancy complicated by pre-eclampsia and FGR can be replicated in vitro by ROS (Reactive oxygen species) or hypoxia, supporting their involvement in the pathogenesis of these conditions.^[19]

Tenny and Parker (1940) quoted that the influence of maternal factors is best shown in preeclampsia where the decreased intervillous blood flow finally leads to increased syncytial knotting, so called the Tenny-Parker changes. He emphasized that the increased bridging of placental syncytium producing knots, is very much characteristic of preeclampsia. Syncytial knots are also seen normally in term and preterm placentae but there number is much increased in toxemia.^[20]

In the study group, there was a higher percentage of stromal fibrosis correlating with increasing severity of disease. Similar to our study, Harienne et al also found significant level of stromal fibrosis in cases of toxemia and they explained that the two main factors responsible for the formation of stromal fibrosis are normal aging and reduced blood flow. This hypothesis explains the findings of the present study, the high incidence of villous fibrosis in placenta is probably due to the reduction of the fetal blood flow by obliterative endarteritis of the fetal stem arteries.^[21,22]

CONCLUSION

When there is insufficient compensatory changes in the placenta to hypoxia, there is failure to develop and form an adequate placental mass which subsequently affecting the placental morphometry, gross and histomorphology.

In the present study, it was demonstrated that the placental morphometry like placental weight and volume correlates with the severity of the disease and

fetal outcome. Hence, a thorough examination of the placenta is required to gain the insight of the status of fetus in the antenatal period as it act as an indicator to the overall development of the fetus in preeclamptic cases. The Placental volume can be found out in utero with the help of three-dimensional ultrasonography and Virtual Organ Computer – Aided Analysis (VOCAL). Hence condition of the fetus and its growth can be assessed and early measures can be taken to prevent fetal mortality and morbidity.

REFERENCES

1. Sinhal L, Bhargawa S, Tater A, Jain M, Jawa, Acharya V. The Placental changes in hypertensive disorder of pregnancy and compare with normal pregnancy. 2015 Jul-Sep;2(3):108-14.
2. Lamarca B. Endothelial dysfunction. An important mediator in the pathophysiology of hypertension during preeclampsia. *Minerva Ginecol.* 2012;64(4):309-20.
3. Cunningham FG, Leveno KJ, Bloom SL, Hauth JC, Gilstrap III LC, Wenstrom KD. *Williams's Obstetrics.* 22nd ed. New York, NY: McGraw Hill Professional; 2005. pp91-119
4. Mirro R, Brown DR. Edema, proteinuria, thrombocytopenia, and leucopenia in infants of preeclamptic mothers. *American Journal of Obstetrics and Gynaecology.* 1982;144:851-2
5. Schmidt BK, Muraji T, Zipursky A. Low antithrombin III in neonatalshock: DIC or non-specific protein depletion? *Europ J Pediatr.* 1986 Dec;145(6):500-3.
6. Llonche PS, Mane AB. Morphometric study of placenta and its correlation in normal and hypertensive pregnancies. *International Journal of Pharma and Bio Sciences.* 2011 Oct-Dec;4(2):22937
7. Llonche PS, Mane AB. Morphometric study of placenta and its correlation in normal and hypertensive pregnancies. *International Journal of Pharma and Bio Sciences.* 2011 Oct-Dec;4(2):229-37
8. Kher AV, Zavar AP. Study of placental pathology in toxemia of pregnancy and its fetal complications. *Indian Journal of Pathology and Microbiology.* 1981;24:245.
9. Majumdar S, Dasgupta H, Bhattacharya K, Bhattacharya A. A study of placenta in normal and hypertensive pregnancies. *J Anat Soc India.* 2005;54(2):1-9.
10. Llonche PS, Mane AB. Morphometric study of placenta and its correlation in normal and hypertensive pregnancies. *International Journal of Pharma and Bio Sciences.* 2011 Oct-Dec;4(2):229-37.
11. Pasricha N. Placental morphology and its co-relation with foetal outcome in pregnancy-induced hypertension. *International Journal of Basic and Applied Medical Sciences.* 2012 Sep;2(3):120-5.
12. Fox H. *Pathology of the placenta.* 2nd ed. London: WB Saunders Company Ltd; 1997.
13. Kurdukar MD, Deshpande NM, Shete SS, Zavar MP. Placenta in PIH. *Indian J Pathol Microbiol.* 2007;50:493- 7.
14. Kambale T, Iqbal B, Ramraje S, Swaimul K, Salve S. Placental morphology and fetal implications in pregnancies complicated by pregnancy-induced hypertension. 2018; IP:223.237.193.85
15. Brandt G. *Atiologie und Pathogenese der kalkablagerung in der plazenta.* *Geburtshilfe und Frauenheilkunde.* 1973;33:119-24.
16. Gore CR, Pandey A, Shetty A, Rao R, Paranjape S. A study on histopathological changes in placenta in pre- eclampsia/ eclampsia: A case- control study in tertiary care centre, western India. *Indian Journal of Pathology and Oncology.*2018; 5(3):385-390
17. Kurdukar MD, Deshpande NM, Shete SS, Zavar MP. Placenta in PIH. *Indian J Pathol Microbiol.* 2007;50:493- 7.
18. Salmani D, Purushothaman S, Somashekara SC, Gnanagurudasan E, Sumangaladevi K, Harikishan R, Venkateshwarareddy M. Study of structural changes in

- pregnancy-induced hypertension. *Journal of natural science, biology and medicine*. 2014; 5(2): 352-355
19. Heazell AEP, Moll SJ, Jones CJP, Baker PN, Crocker IP. Formation of syncytial knots is increased by hyperoxia, hypoxia and reactive oxygen species. *Placenta*. 2007 Apr;28: S33-S40.
 20. Tenney B, Parker F. The placenta in toxemia of pregnancy. *American Journal of Obstetrics and Gynaecology*. 1940;39:1000-5.
 21. Fox H. *Pathology of the placenta*. Philadelphia: Saunders; 1978
 22. Dhabai p, Gupta G, Bapna N. Histological study of human placenta in normal and pregnancy induced hypertension (PIH) cases. 2013 Nov;2(11):30-5.